

Magnesium sulfate for control of muscle rigidity and spasms and avoidance of mechanical ventilation in pediatric tetanus

Gary D. Ceneviva, MD; Neal J. Thomas, MD; Deborah Kees-Folts, MD

Objective: To describe the use of intravenous magnesium sulfate for the control of muscle spasms and severe generalized rigidity in a child with moderate to severe tetanus without the need for prolonged deep sedation, mechanical ventilation, or neuromuscular blockade.

Design: Case report.

Setting: Pediatric intensive care unit in a tertiary care, university-based children's hospital.

Interventions: A continuous infusion of magnesium sulfate.

Measurements and Main Results: We describe a 12-yr-old child with moderate to severe tetanus who was treated with a continuous infusion of magnesium sulfate to control painful muscle spasms and severe generalized rigidity initially refractory to moderate sedation. Muscle spasms and severe generalized rigidity were improved with magnesium sulfate. No adverse effects

associated with the use of magnesium sulfate were noted during the monitoring of cardiovascular and respiratory function, reflexes, and serum magnesium concentrations.

Conclusions: An infusion of magnesium sulfate can be utilized to treat muscle spasms and severe generalized rigidity without the need for deep sedation, mechanical ventilation, or neuromuscular blockade. We recommend that magnesium sulfate be considered in the armamentarium of therapeutics utilized to treat muscle spasms and rigidity associated with tetanus, provided the patient's neurologic, cardiovascular, and respiratory status can be closely monitored in the pediatric intensive care unit. (*Pediatr Crit Care Med* 2003; 4:480–484)

KEY WORDS: tetanus; muscle spasms; rigidity; magnesium sulfate

Since the implementation of a widespread tetanus immunization program for children and routine boosters every 10 yrs, the reported incidence of tetanus morbidity and mortality in the United States has declined substantially since the mid-1940s (1). However, despite the availability of a safe and effective vaccine against tetanus, 124 cases of the disease were reported to the Centers for Disease Control's National Notifiable Disease Surveillance System between 1995 and 1997 (2). Five of the cases (4%) occurred in children <14 yrs of age, including one neonate. During the past decade, the case fatality rate from tetanus reported to the Centers for Disease Control has ranged between 11% and 25% (1, 2). In children requiring artificial ventilation, the reported case fatality rate is substantially higher (3). Frequently, the cause of mor-

tality in both adults and children with severe tetanus requiring mechanical ventilation tends to be attributed to complications of intensive care treatment rather than to the disease process itself (3–6). These complications include pneumonia, septicemia, pneumothoraces, gastrointestinal hemorrhage, and pulmonary embolism.

The principles of tetanus management include neutralization of unbound toxin, eradication of the source of toxin, control of muscle rigidity and spasm, treatment of autonomic dysfunction, and supportive intensive care (5, 7, 8). Supportive intensive care therapy includes airway stabilization via tracheostomy or intubation, deep sedation to control autonomic dysfunction and muscle spasms, and artificial ventilation with or without neuromuscular blockade (5–10). Although lifesaving, supportive intensive care can result in a number of complications. Thus, there remains a continuing search for therapies that can control muscle spasms and rigidity without the need for prolonged deep sedation or artificial ventilation. Opioids (4, 9, 11, 12), benzodiazepines (3–6, 9, 10), baclofen (13–17), dantrolene (18–21), and propofol (22) have all been utilized in cases of severe

tetanus to control muscle spasms and rigidity. However, adverse effects associated with these therapies often limit their use.

The use of magnesium has been described for the control of autonomic dysfunction (23–26) and muscle spasms and rigidity (27–29) associated with severe tetanus in adults. To date, the descriptive use of magnesium sulfate to control muscle spasms and severe muscle rigidity associated with tetanus in children is lacking. Therefore, we will describe a 12-yr-old child with moderate to severe tetanus who was treated with a continuous infusion of magnesium sulfate to control painful muscle spasms and severe generalized rigidity initially refractory to moderate sedation without the need for prolonged deep sedation, mechanical ventilation, or neuromuscular blockade.

CASE REPORT

A 12-yr-old unimmunized Amish boy weighing 32 kg was admitted to the pediatric intensive care unit at a regional tertiary care center with a history of progressive generalized, painful muscle rigidity, trismus, dysphagia, difficulty chewing, nuchal rigidity, and intermit-

From the Divisions of Pediatric Critical Care Medicine (GDC, NJT) and Pediatric Nephrology (DKF), Penn State Children's Hospital, Penn State University College of Medicine, Hershey, PA.

Copyright © 2003 by the Society of Critical Care Medicine and the World Federation of Pediatric Intensive and Critical Care Societies

DOI: 10.1097/01.PCC.0000090015.03962.8B

tent muscle spasms. Ten days before admission, he lacerated his left elbow with a cement block that had been sitting in manure. There was no history of fever, intravenous drug use, ingestion, or animal bites. The initial vital signs were remarkable for a blood pressure of 118/67 mm Hg, a pulse of 90 beats/min, a respiratory rate of 27 breaths/min, and a temperature of 37.8°C. The physical exam demonstrated generalized and painful muscle rigidity with intermittent muscle spasms, trismus, risus sardonicus, nuchal rigidity, mild opisthotonus, abdominal rigidity, and an inability to walk or sit up without assistance. The patient's sensorium was clear. Admission laboratory evaluation revealed a normal white blood cell count and electrolytes, including an ionized calcium and renal function. An elevated serum creatine phosphokinase of 298 IU/L (normal, 20–180 IU/L) was noted. A thorough evaluation for infectious or toxicologic causes of his symptoms was negative. Under public health surveillance guidelines, the Centers for Disease Control defines a clinical diagnosis of tetanus as the acute onset of hypertonia or painful muscular contractions and generalized muscle spasms without other apparent medical causes (30). By utilizing this definition, a diagnosis of tetanus was made on clinical grounds. Clinically, tetanus has been divided into three grades: benign, moderate, and severe (31). Our patient displayed characteristics of both moderate and severe tetanus. The characteristics of moderate severity included a low-grade fever and dysphagia, and the characteristics of severe tetanus included an incubation period of <10 days, severe spasms, and intense generalized muscle rigidity. According to this grading classification, patients with moderate to severe tetanus normally require sedation and potentially neuromuscular blockade.

Utilizing standard therapy for muscle spasms and severe rigidity due to tetanus, the patient's spasticity was initially treated with lorazepam and morphine. A physical, occupational, and speech therapy evaluation and program were also initiated and continued throughout the hospitalization. However, the severe pain associated with the muscle rigidity and intermittent spasms continued, despite high enough doses of sedatives and analgesics that respiratory depression became a serious concern. Therefore, a continuous magnesium sulfate infusion at 125 mg/hr (100 mg·kg⁻¹·day⁻¹) was added

approximately 6 hrs after admission to avoid further progression of the disease requiring endotracheal intubation and mechanical ventilation. To ensure that the patient did not have untoward effects of the magnesium infusion, hourly vital signs and neurologic exams were performed. Neurologic exams included an evaluation of the degree of muscular spasticity, rigidity, and patellar reflexes. The attenuation of patellar reflexes was utilized as a clinical measure of magnesium toxicity. To follow the degree of respiratory insufficiency, serial vital capacities were performed. To obtain an objective measure of the degree of muscle spasticity, serum creatine phosphokinase was followed every 8 hrs. Within 24 hrs of the addition of continuous magnesium infusion, both the severity of spasms and degree of muscular rigidity decreased. Concurrently, the serum creatine phosphokinase, which were initially elevated, normalized (Fig. 1). The tachypnea subsequently improved, and serial vital capacities also showed noticeable improve-

ment after the institution of magnesium sulfate (Fig. 2).

By hospital day 4, morphine sulfate, which was initially administered for painful spasms, was discontinued without any further complaints of pain. On hospital days 6–10, the lorazepam infusion was gradually weaned and subsequently discontinued. On day 11, an attempt to wean the magnesium sulfate infusion was made, but the patient developed increased painful muscle rigidity within 24 hrs of this weaning attempt, and the magnesium infusion was increased back to 125 mg/hr with ablation of spasms. Subsequently, the magnesium was gradually discontinued during the following 5 days. The total duration of magnesium therapy was 15 days. After 17 days, the patient was successfully discharged to home with no untoward effects of his disease noted. Of note, the patient never required prolonged deep sedation, intubation, tracheostomy, mechanical ventilation, or neuromuscular blockade.

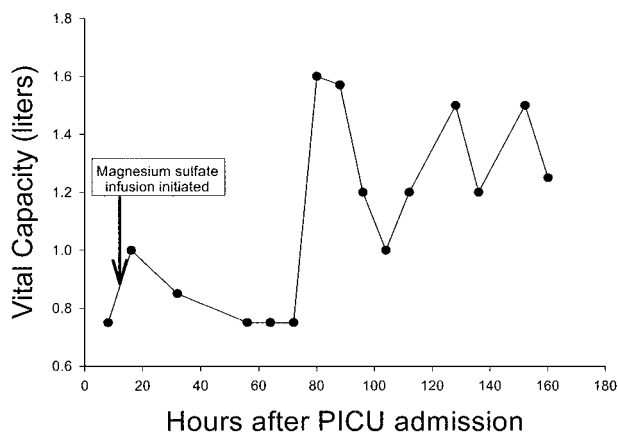


Figure 1. Vital capacity levels over time after admission to the pediatric intensive care unit (PICU).

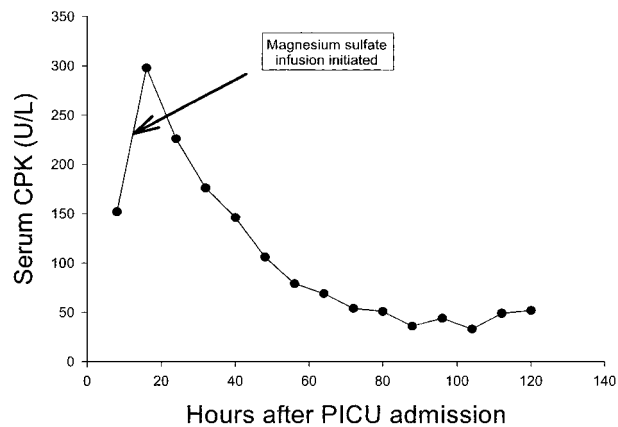


Figure 2. Serum creatine phosphokinase (CPK) levels over time after admission to the pediatric intensive care unit (PICU).

During the magnesium infusion, there was no evidence of autonomic dysfunction. There was no evidence of hypertension or hypotension. Continuous electrocardiographic monitoring revealed no arrhythmias or heart block. Throughout the hospitalization, no adverse respiratory effects of magnesium, including laryngospasm, stridor, respiratory muscle paralysis, or apnea, were observed. Serum magnesium concentrations were maintained between 2.1 and 2.7 mEq/L without any evidence of adverse effects, including hypocalcemia.

DISCUSSION

The causative organism of tetanus is *Clostridium tetani*, a Gram-positive anaerobic bacillus. The spores of *C. tetani* are found in both the soil and feces of animals and humans (32). Although highly resistant to temperature extremes and disinfectants, the organism is sensitive to many common antibiotics (33). *C. tetani* produces two toxins: tetanospasmin and tetanolysin. Tetanospasmin is the toxin primarily responsible for the central nervous system and autonomic manifestations of the disease. In the central nervous system, tetanospasmin prevents the release of γ -aminobutyric acid and glycine (34, 35). The resultant lack of this inhibitory input leads to the muscle rigidity seen in tetanus.

Generalized tetanus is the most common presentation of the disease, and it is frequently associated with muscle rigidity, generalized spasms, and autonomic instability (8). The time from initial inoculation to the onset of symptoms is known as the incubation period. Most patients develop symptoms within 2 wks of inoculation (8). Muscle rigidity is usually first observed in the facial muscles, with progression to the neck, trunk, and limbs. Initially, patients often present with trismus (36). Subsequently, risus sardonicus, dysphagia, nuchal rigidity, pain or stiffness in the shoulders and back muscles, abdominal rigidity, stiffness and extension of the limbs, and opisthotonos can occur. As generalized tetanus progresses, reflex muscle spasms begin to develop. The time from the onset of symptoms to the development of muscle spasms is called the onset time, which varies between 1 and 7 days. Shorter incubation periods and onset times are associated with more severe disease (7, 8, 33). Clinically, the first week of illness is characterized by muscle rigidity and

spasms, which increase in severity. Spasms reduce after 2–3 wks, but stiffness can persist much longer (7). Muscle rigidity and spasms can restrict ventilation, leading to hypoxia, atelectasis, reduced chest wall compliance, and apnea (7, 8, 33).

Despite the widespread availability of tetanus immunizations and vast improvements in critical care medicine, tetanus remains a frustrating clinical problem. Intensive care management continues to be mainly supportive and includes airway stabilization, deep sedation to control autonomic dysfunction and muscle spasms, and artificial ventilation with or without neuromuscular blockade when sedation alone is inadequate (5–10). Children with moderate to severe tetanus requiring mechanical ventilation tend to have a higher rate of mortality than those children not requiring long-term mechanical ventilation (3). Although lifesaving, supportive intensive care can also result in a number of complications, including pneumonia, sepsis, pneumothoraces, pulmonary emboli, and gastric hemorrhage (3–6). Therefore, alternative therapies to control muscle rigidity and spasms without the need for deep sedation, paralysis, and artificial ventilation are needed.

Analgesics are often a necessity to control the pain associated with severe muscle rigidity and spasms. Opiates, especially morphine, are commonly used to control sympathetic overactivity (37, 38) and pain associated with severe muscle spasms (4, 9, 11, 12). Morphine induces a peripheral reflex reduction in sympathetic α -adrenergic tone and attenuation of central sympathetic efferent discharge, resulting in peripheral venous and arteriolar dilation (39). In addition to the intravenous route, morphine has also been utilized via intrathecal and epidural administration to control painful spasms and facilitate ventilation (11, 12). However the doses and frequency required to control muscle spasms can result in respiratory depression (11). In addition to respiratory depression, morphine is associated with a number of adverse effects, including seizures, changes in mental status, bradycardia, venodilation, nausea, vomiting, decreased gastrointestinal motility, pruritus, physical dependence, and withdrawal (40).

Benzodiazepines, γ -aminobutyric acid agonists, have been utilized to control muscle rigidity and the severe spasms of tetanus, and they may indirectly antagonize the toxic effects of tetanospasmin

(33). Thus, the use of benzodiazepines for sedation, amnesia, and muscle relaxation is often considered a standard of care in the management of tetanus (5, 7, 8, 33). However, the doses required to achieve adequate control of muscle rigidity and spasms can result in respiratory depression and coma, requiring mechanical ventilation (41, 42). In addition, parenteral diazepam and lorazepam contain propylene glycol, which may increase the risk of lactic acidosis (8, 43). Abrupt discontinuation of prolonged benzodiazepine therapy may precipitate withdrawal (44).

Intrathecal baclofen, a specific γ -aminobutyric acid-B agonist, has been utilized to treat muscle rigidity and spasms in tetanus (13–17). Saissy et al. (15) prospectively evaluated repeated intrathecal injections of baclofen in the treatment of ten patients with severe tetanus. Five of the ten patients treated developed coma and respiratory depression, which was attributed to the intrathecal baclofen. Other adverse effects of intrathecal baclofen include coma, hypotension, bradycardia, and meningitis (15–17, 45).

Intravenous dantrolene, which interferes with the release of calcium from the sarcoplasmic reticulum, resulting in muscle relaxation (46), has been reported to be effective in relieving muscle spasticity and rigidity associated with tetanus (18–21). In children, dantrolene-treated patients with tetanus had a significantly reduced rate of mortality when compared with a historical control group (21). However, dantrolene therapy may be associated with hepatotoxicity (18–20), and therefore, its use is also limited.

Propofol has been utilized in adults to control muscle spasms and rigidity without neuromuscular blockade (22). However, the drug levels utilized were closer to anesthetic than sedative concentrations, necessitating mechanical ventilation. In children, continuous infusions of propofol have resulted in progressive metabolic acidosis bradyarrhythmia, incremental myocardial failure, and death (47, 48). As a result, the Food and Drug Administration has issued a warning against the use of continuous infusions of propofol for sedation in the pediatric population.

The use of magnesium has been described for the control of autonomic dysfunction (23–26), muscle spasms, and rigidity (27–29) associated with severe tetanus in adults. Magnesium has effects on both the presynaptic and postsynaptic

terminals (49). Magnesium competitively blocks calcium entry into the presynaptic terminal, which impairs neuromuscular transmission by reducing acetylcholine release. Magnesium also decreases the postsynaptic sensitivity of the motor endplate to acetylcholine. In 1906, the treatment of severe tetanus with intrathecal magnesium sulfate was first described (27). Subsequently, intravenous magnesium has been utilized in both adults and children as an adjunctive therapy for the management of autonomic dysfunction in severe tetanus (23–26). In a pilot study, Attygalle and Rodrigo (28) performed a prospective study investigating the ability of magnesium sulfate to control the spasms and rigidity of severe tetanus without the need for sedation and artificial ventilation. In all eight adult patients studied, serum magnesium concentrations maintained within a therapeutic range safely and effectively controlled muscle spasms and rigidity without the need for additional sedation or ventilatory support, except when indicated for lung pathology. Subsequently, these same authors conducted a prospective, observational study examining the efficacy and safety of magnesium sulfate for control of spasms and rigidity and the need for ventilatory support in 40 adult patients with tetanus (29). Muscle spasms and rigidity were controlled in 38 of the 40 patients without the need for neuromuscular blockade. However, tracheostomy and frequent suctioning were necessary in all patients due to increased respiratory secretions and an ineffective cough. In addition, unlike the pilot study, 17 of 40 patients (43%) required ventilatory support.

In this report, we described the use of intravenous magnesium sulfate to control muscle spasms and severe rigidity in a child with moderate to severe tetanus without the need for prolonged deep sedation, invasive airway interventions, mechanical ventilation, or neuromuscular blockade. In our patient, standard therapy, which included escalating doses of opioids and benzodiazepines, were unsuccessful in controlling the patient's muscle spasms and severe rigidity. In tetanus, the focus on supportive intensive care is often directed at managing respiratory complications. Spasms of the laryngeal muscles can precipitate acute airway obstruction and subsequent asphyxia. Muscle spasms and rigidity of the chest wall and respiratory muscles may interfere with ventilation either pri-

marily or secondarily as a result of retained secretions, atelectasis, or pneumonia. Potentially, the use of sedation to control muscle spasms and rigidity can lead to obtundation and central respiratory depression. Most children diagnosed with moderate to severe tetanus require sedation, airway control, and artificial ventilation with or without neuromuscular blockade. By utilizing the grading system of severity presented by Veronesi and Focaccia (31), our patient was determined to have moderate to severe tetanus. Most likely, our patient would have required control of the airway and artificial ventilation with or without neuromuscular blockade to manage potential respiratory complications caused by a combination of severe muscle rigidity, spasms, and escalating doses of sedatives. However, with the addition of intravenous magnesium to the therapeutic armamentarium, we were able to avoid intubation, tracheostomy, and mechanical ventilation. The adverse effects of mechanical ventilation can include ventilator-associated pneumonia, volutrauma or lung overdistension, barotrauma, pneumothoraces, increased extravascular lung water, alterations in cardiovascular hemodynamics, decreased organ perfusion, and injury to the glottis, larynx, or trachea (50). Chronic administration of analgesics or sedatives is frequently associated with tachyphylaxis, and escalating dosage requirements can lead to dependency, necessitating a slow withdrawal (40). Currently, no single drug or group of drugs has been consistently effective in controlling spasms in severe tetanus while avoiding such complications.

To determine whether any adverse effects associated with magnesium occurred in our patient, several variables were measured in the pediatric intensive care unit. Continuous electrocardiography, serial blood pressures, respiratory frequency, vital capacities, neurologic examinations including patellar reflexes, and serum magnesium and calcium levels were frequently monitored. Often, the severity of adverse cardiovascular changes seems to be associated or correlated directly with the plasma magnesium concentration (51). Moderate elevations in the plasma magnesium concentration above 4–5 mEq/L may result in bradycardia or hypotension. Magnesium concentrations between 5 and 10 mEq/L may result in prolongation of the P-R, QRS, and QT intervals. Complete heart block and asystole may occur at

A *n infusion of magnesium sulfate can be utilized to treat muscle spasms and severe generalized rigidity without the need for deep sedation, mechanical ventilation, or neuromuscular blockade.*

plasma magnesium concentrations of 15 mEq/L. Hypermagnesemia may also result in neuromuscular abnormalities. Clinically, one of the earliest effects of magnesium toxicity is a decrease or disappearance of the deep tendon reflexes, which can occur at plasma magnesium levels of 4 mEq/L. Somnolence can occur at levels of 4–7 mEq/L. Muscle paralysis and apnea may occur at magnesium concentrations of ≥ 10 mEq/L. The patellar reflex was closely monitored throughout the study for any attenuation. Because areflexia occurs only at serum magnesium concentrations of >4 , the patellar reflex proved a valid clinical end point in our patient to ensure that the therapeutic range was not exceeded. In our patient, the mean magnesium level was maintained between 2.1 and 2.7 mEq/L. Our patient demonstrated no evidence of any adverse cardiovascular effects as measured by continuous electrocardiographic monitoring and serial blood pressures. Parenteral magnesium has also been associated with hypocalcemia, which did not occur in our patient.

In summary, tetanus is a serious, life-threatening, but uncommon problem encountered in the pediatric intensive care unit. Although the mainstay of intensive care therapy remains supportive, we report the use of intravenous magnesium sulfate in a pediatric patient to control muscle spasms and severe rigidity without the need for prolonged deep sedation, paralysis, artificial ventilation, or the complications associated with these therapies. Because tetanus is an infrequent diagnosis, it is unlikely that a prospective, randomized trial utilizing magnesium sulfate as a sole agent for the control of spasms without the need for deep sedation or artificial ventilation will be per-

formed in the pediatric population. However, we recommend that magnesium sulfate be considered in the armamentarium of therapeutics utilized to treat muscle spasms and rigidity associated with tetanus, provided the patient's neurologic, cardiovascular, and respiratory status can be closely monitored in the pediatric intensive care unit.

REFERENCES

- Izurieta HS, Sutter RW, Strebel PM, et al: Tetanus surveillance: United States, 1991–1994. *MMWR CDC Surveill Summ* 1997; 46(SS-2):15–25
- Bardenheier B, Prevost DR, Khetsuriani N, et al: Tetanus surveillance: United States, 1995–1997. *MMWR CDC Surveill Summ* 1998; 47(SS-2):1–12
- Wesley AG, Pather M: Tetanus in children: An 11-year review. *Ann Trop Paediatr* 1987; 7:32–37
- Edmondson RS, Flowers MW: Intensive care in tetanus: Management, complications and mortality in 100 cases. *BMJ* 1979; 1:1401–1404
- Singhi S, Jain V, Subramanian C: Post-neonatal tetanus: Issues in intensive care management. *Indian J Pediatr* 2001; 68: 267–272
- Udwadia FE, Lall A, Udwadia ZF, et al: Tetanus and its complications: Intensive care and management experience in 150 Indian patients. *Epidemiol Inf* 1987; 99:675–684
- Cook TM, Protheroe RT, Handel JM: Tetanus: A review of the literature. *Br J Anaesth* 2001; 87:477–487
- Ernst ME, Klepser ME, Fouts M, et al: Tetanus: Pathophysiology and management. *Ann Pharmacother* 1997; 31:1507–1513
- Sun KO, Chan YW, Cheung RTF, et al: Management of tetanus: A review of 18 cases. *J R Soc Med* 1994; 87:135–137
- Jolliet P, Magnenat JL, Kobel T, et al: Aggressive intensive care treatment of very elderly patients with tetanus is justified. *Chest* 1990; 97:702–705
- Miller MT: Epidural morphine in the treatment of tetanus. *S Afr Med J* 1983; 63:31
- Sun S, Dolan D, Ozenc E: Intrathecal morphine in tetanus. *Br J Anaesth* 1982; 54: 699–700
- Muller H, Borner U, Zierski J, et al: Intrathecal baclofen for treatment of tetanus-induced spasticity. *Anesthesiology* 1987; 66:76–79
- Dressnandt J, Konstanzer A, Weinzierl FX, et al: Intrathecal baclofen in tetanus: Four cases and a review of reported cases. *Intensive Care Med* 1997; 23:896–902
- Saissy JM, Demaziere J, Vitris M, et al: Treatment of severe tetanus by intrathecal injections of baclofen without artificial ventilation. *Intensive Care Med* 1992; 18:241–244
- Engrand N, Guerot E, Rouamba A, et al: The efficacy of intrathecal baclofen in severe tetanus. *Anesthesiology* 1999; 90:1773–1776
- Boots RJ, Lipman J, O'Callaghan J, et al: The treatment of tetanus with intrathecal baclofen. *Anaesth Intensive Care* 2000; 28:438–442
- Farquhar I, Hutchinson A, Curran J: Dantrolene in severe tetanus. *Intensive Care Med* 1988; 14:249–250
- Checketts MR, White RJ: Avoidance of intermittent positive pressure ventilation in tetanus with dantrolene therapy. *Anaesthesia* 1993; 48:969–971
- Tidyman M, Prichard JG, Deamer RL, et al: Adjunctive use of dantrolene in severe tetanus. *Anesth Analg* 1985; 64:538–540
- Aguilar Bernal OR, Bender MA, Lacy ME: Efficacy of dantrolene sodium in management of tetanus in children. *J R Soc Med* 1986; 79:277–281
- Borgeat A, Popovic V, Schwander D: Efficiency of a continuous infusion of propofol in a patient with tetanus. *Crit Care Med* 1991; 19:295–297
- Lipman J, James MFM, Erskine J, et al: Autonomic dysfunction in severe tetanus: Magnesium sulfate as an adjunct to deep sedation. *Crit Care Med* 1987; 15:987–988
- Ho SH, Lim SH, Loo S: The use of magnesium sulphate in the intensive care management of an Asian patient with tetanus. *Ann Acad Med Singapore* 1999; 28:586–589
- James MFM, Manson EDM: The use of magnesium sulphate infusions in the management of very severe tetanus. *Intensive Care Med* 1985; 11:5–12
- Sutton DN, Tremlett MR, Woodcock TE, et al: Management of autonomic dysfunction in severe tetanus: The use of magnesium sulphate and clonidine. *Intensive Care Med* 1990; 16:75–80
- Blake JA: The use of magnesium sulphate in the production of anaesthesia and in the treatment of tetanus. *Surg Gynecol Obstet* 1906; 2:541–550
- Attygalle D, Rodrigo N: Magnesium sulphate for control of spasms in severe tetanus: Can we avoid sedation and artificial ventilation? *Anaesthesia* 1997; 52:956–962
- Attygalle D, Rodrigo N: Magnesium as first line therapy in the management of tetanus: A prospective study of 40 patients. *Anaesthesia* 2002; 57:778–817
- Case definitions for public health surveillance. Centers For Disease Control. *MMWR* 1990; 39(RR-13)
- Veronesi R, Focaccia R: The clinical picture. In: Tetanus: Important Concepts. Veronesi R (Ed). Princeton, NJ, Excerpta Medica, 1981, p 183
- Wilkins CA, Richter MB, Hobbs WB, et al: Occurrence of *Clostridium tetani* in soil and horses. *S Afr Med J* 1988; 73:718–720
- Bleck TP: Tetanus: Pathophysiology, management, and prophylaxis. *Dis Mon* 1991; 37:551–603
- Curtis DR, Felix D, Game CJA, et al: Tetanus toxin and the synaptic release of GABA. *Brain Res* 1973; 51:358–362
- Price DL, Griffin JW: Immunocytochemical localization of tetanus toxin to synapses of spinal cord. *Neurosci Lett* 1981; 23:149–155
- Alfery DD, Rauscher LA: Tetanus: A review. *Crit Care Med* 1979; 7:176–181
- Rie MA, Wilson RS: Morphine therapy controls autonomic hyperactivity in tetanus. *Ann Intern Med* 1978; 88:653–654
- Rocke DA, Wesley AG, Pather M, et al: Morphine in tetanus: The management of sympathetic nervous system overactivity. *S Afr Med J* 1986; 70:666–668
- Zelis R, Mansour EJ, Capone RJ, et al: The cardiovascular effects of morphine. *J Clin Invest* 1974; 54:1247–1258
- Yaster M, Bean JD, Schulman SR, et al: Pain, sedation, and postoperative anesthetic management in the pediatric intensive care unit. In: Textbook of Pediatric Intensive Care. Third Edition. Rogers MC (Ed). Baltimore, Williams and Wilkins, 1996, pp 1547–1593
- Kendall MJ, Clarke SW: Prolonged coma after tetanus. *BMJ* 1972; 1:354–355
- Oduote KA, George BO, Femi-Pearse D: Favourable prognosis of prolonged coma associated with large doses of diazepam in severe tetanus. *Trop Geogr Med* 1976; 28: 194–198
- Kapoor W, Carey P, Karpf M: Induction of lactic acidosis with intravenous diazepam in a patient with tetanus. *Arch Intern Med* 1981; 141:944–945
- Fonsmark L, Rasmussen YH, Carl P: Occurrence of withdrawal in critically ill children. *Crit Care Med* 1999; 27:196–199
- Romijn JA, van Lieshout JJ, Velis DN: Reversible coma due to intrathecal baclofen. *Lancet* 1986; 2:696
- VanWinkle WB: Calcium release from skeletal muscle sarcoplasmic reticulum: Site of action of dantrolene sodium. *Science* 1976; 193:1130–1131
- Parke TJ, Stevens JE, Rice AS, et al: Metabolic acidosis and fatal myocardial failure after propofol infusion in children: Five case reports. *BMJ* 1992; 305:613–616
- Bray RJ: Propofol infusion in children. *Paediatr Anaesth* 1998; 8:491–499
- Krendel DA: Hypermagnesemia and neuromuscular transmission. *Semin Neurol* 1990; 10:42–45
- Martin LD, Bratton SL, Walker LK: Principles and practice of respiratory support and mechanical ventilation. In: Textbook of Pediatric Intensive Care. Third Edition. Rogers MC (Ed). Baltimore, Williams and Wilkins, 1996, pp 307–311
- Rude RK, Singer FR: Magnesium deficiency and excess. *Annu Rev Med* 1981; 32: 245–259